



PATIENT

Pork Chop Willet

SPECIES

Canine

BREED

Dachshund

SEX

Male Neutered

AGE

13 years

WEIGHT

14lbs

INTERPRETED BY

Maggie Machen Lamy,
DVM, DACVIM
(Cardiology)

IMAGING PERFORMED BY

Sarah Pender, CVT

HOSPITAL NAME

SVS Imaging QC

REFERRING VET

Dr. Van Noy

INVOICE

23602

DATE

4/12/22

PRESENTING CLINICAL SIGNS

History: Heart murmur, grade 4/6. BP: 100, 102, 102mmHg.

-Current medications: galliprant 20mg, benazepril 5mg, and furosemide 12.5mg.

-Abnormal PE/Chem/CBC/UA Results: Has urolith, mineralization in kidneys, and multiple stones in urethra within the os penis. Liver margins upper normal to mildly enlarged. Mild elevation in BUN, Creat and USG okay as of December.

RADIOGRAPHIC FINDINGS *NOTE: Images submitted for supplemental cardiac information only. Mild cardiomegaly. No obvious evidence of CHF.

ELECTROCARDIOGRAPHIC FINDINGS *Note: Single lead ECGs are evaluated as a rhythm strip. Morphology/MEA cannot be definitively commented on.

A single lead ECG is available; 25mm/s, 10mm/mV. The average heart rate is 100bpm (range 78-125bpm). The rhythm is sinus in origin, with a p for every QRS complex and vice versa. The P and QRS morphologies are positive. No ectopic beats, pauses or other dysrhythmias observed. ECG diagnosis: Normal sinus rhythm with respiratory variation.

ECHOCARDIOGRAM FINDINGS

2D, m-mode, color flow and doppler imaging is available. Mild diffuse thickening of mitral valve leaflets with no prolapse into the left atrial lumen. Mild eccentric mitral regurgitation with mild left atrial dilation. Normal LV diameter with adequate myocardial function. The tricuspid valve appears normal with no tricuspid regurgitation. Normal right atrial and ventricular diameter and morphology indicating no overt evidence of pulmonary arterial hypertension. The pulmonic and aortic valves are normal in morphology and mobility. Normal pulmonic and aortic outflow velocities with laminar flow. No obvious aortic or pulmonic insufficiency. No pericardial or pleural effusion noted. No obvious cardiac masses.

CARDIAC CHART

| CANINE CARDIAC PARAMETERS | MR VMAX (m/s) | TR VMAX (m/s) | LA/AO (Boon method) | LA/AO (Heart Base; Swe) | FS (%) | EF (%) | EPSS (cm) |
|---|---------------|---------------|---------------------|-------------------------|---------------------------------|--|--|
| NORMAL PARAMETER | 4.5-5.5 | <2.7 | 1.3 | <1.6 | 28-40 | 40-100 | <0.6 |
| PATIENT | NM | NA | NM | 1.5 | 42 | 76 | 0.3 |
| CANINE CARDIAC PARAMETERS | HR (BPM) | AV VMAX (m/s) | PV MAX (m/s) | BODY WEIGHT (kg) | LA 2D short axis Base view (cm) | LVIDd Avg; 2D and m-mode short axis (cm) | LVIDs Avg; 2D and m-mode short axis (cm) |
| NORMAL PARAMETER | 50-100 | 0.7-1.7 | 0.7-1.6 | BELOW | BELOW | BELOW | BELOW |
| PATIENT | 80 | 1.1 | 0.62 | 6.4 | 2.2 | 2.1 | 1.2 |
| *Normal chamber parameters expressed as a mean value (SD) | | | | 3 | 1.27 (5.3) | 2.46 (2.46) | 1.36 (5.5) |
| BODY WEIGHT DEPENDENT PARAMETERS | | | | 5 | 1.40 (4.5) | 2.74 (5.2) | 1.60 (4.7) |
| <i>*Note: All measurements based upon multi-modal images and methods. An average value is reported.</i> | | | | 10 | 1.50 (3.8) | 3.27 (3.5) | 2.06 (3.1) |
| | | | | 15 | 1.83 (2.0) | 3.71 (2.4) | 2.43 (2.1) |
| | | | | 20 | 2.02 (1.9) | 4.14 (2.2) | 2.80 (2.0) |
| | | | | 25 | 2.18 (2.4) | 4.48 (2.9) | 3.10 (2.5) |
| | | | | 30 | 2.33 (3.3) | 4.83 (3.9) | 3.39 (3.4) |
| | | | | 35 | 2.48 (4.3) | 5.17 (5.0) | 3.69 (4.5) |
| | | | | 40 | 2.62 (5.2) | 5.48 (6.1) | 3.96 (5.4) |
| | | | | 50 | 2.88 (7.1) | 6.07 (8.3) | 4.46 (7.4) |

Adapted from June Boon, Veterinary Echocardiography, 1998
Rishniw M and Hollis NE, J Vet Intern Med 2000; 14:429-435
Hansson et al, Vet Rad and Ultrasound 2002
Bonagura et al. Echocardiography: principles of interpretation, Vet Clin North Am 15:1177, 1995

**PATIENT**

Pork Chop Willet

SPECIES

Canine

BREED

Dachshund

SEX

Male Neutered

AGE

13 years

WEIGHT

14lbs

INTERPRETED BYMaggie Machen Lamy,
DVM, DACVIM
(Cardiology)**IMAGING PERFORMED BY**

Sarah Pender, CVT

HOSPITAL NAME

SVS Imaging QC

REFERRING VET

Dr. Van Noy

INVOICE

23602

DATE

4/12/22

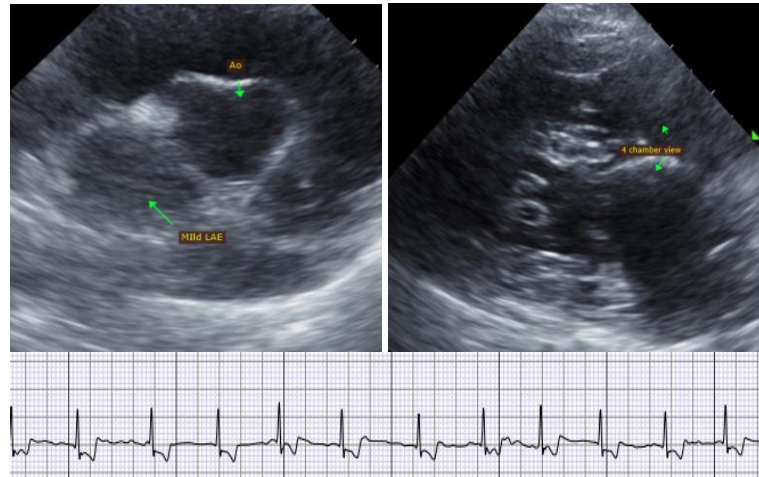
INTERPRETATION OF THE FINDINGS & FURTHER RECOMMENDATIONS

Chronic degenerative valve disease causing mild mitral regurgitation. Lack of significant left atrial enlargement indicates the current risk for complication is low. No concurrent issues such as systolic dysfunction or pulmonary hypertension are noted in this study. The ECG is unremarkable with a respiratory sinus arrhythmia.

Given these findings, no cardiac medications are clearly indicated; **Benazepril and Lasix can be safely discontinued.** Assessment of progression in the future will help predict long term prognosis, which is highly variable at this stage (B1). Omega fatty acid supplementation and mild salt restriction may be of some long-term benefit. Monitor for development of a cough, labored breathing, exercise intolerance or collapse episodes.

Anesthetic risk is considered mild if needed. Cardiac protective drug choices (opioid/benzodiazepine premedication, propofol or alfaxalone induction, isoflurane gas) are recommended. Pre-oxygenate for 5-10 minutes prior to induction. Monitor for arrhythmias, hypotension, and hypoxia both intra and post-operatively and intervene as necessary. Mild IV fluid restriction is recommended to avoid fluid overload. Avoid heart rate stimulating drugs such as atropine unless clinically indicated.

Recommend conservative monitoring with a recheck echocardiogram in 6 months, sooner if any development of clinical signs.

IMAGES

The information and recommendations provided are based on the images presented by the referring veterinarian. No evaluation can be communicated regarding pathology that was not visible in the image/video clips provided.

Thank you for this referral. If the clinical or image interpretation does not parallel your findings or if I can be of any further assistance, please contact me.

Maggie Machen Lamy, DVM
Diplomate of the American College of Veterinary Internal Medicine (Cardiology)
 info@sonopath.com